

Proceedings
of the Danish Institute
at Athens
VIII



The Pit L Baby Burial – Hermeneutics

Implications for immigration into Kydonia in MMIII/LMI

P. J. P. MCGEORGE

Context

This infant burial was discovered in the Ag. Aikaterini Square excavation on Kastelli Hill in 2014.¹ The infant was buried in Pit L, a shallow oval hollow c. 9-14 cm deep and 50 cm long by 30 cm wide, sealed by 3 stone slabs, the widest of which was 35 cm. No grave offerings were found. The burial was stratified below the LM IIIA:2/B:1 Building 2, which in this part of the excavation was constructed deep in the Neopalatial layers. It is therefore securely dated to the MM III/LM I period. At the present time it is the earliest occurrence of an intramural subfloor pit burial in West Crete.²

Skeletal Remains

During the 2014 excavation, some cranial fragments, long bones and ribs of an infant were recovered from Pit L. More skeletal material was retrieved from the residue after water sieving 9 litres of surrounding soil, substantially increasing the amount of material recovered.³ The residue included all of the twelve partially formed, unerupted deciduous teeth; the metacarpals, metatarsals, manual and pedal phalanges; a distal femur fragment, three fragments of a fibula and further cranial fragments including the greater wing of the left sphenoid and three ear bones, reaffirming that water sieving and residue analysis significantly improve the retrieval of fragile skeletal material.

Cranium

The cranial vault bones were eggshell thin and broken into many fragments (Fig. 1); porosity and radial lesions were noted on the endocranial surfaces of the occipital and parietals (Figs 1-3). Denser elements, such as the petrous bones (the right measuring: 29.18 mm long x 16.62 mm wide; the left: 27 mm long x 14.83 mm wide), the left greater wing of the sphenoid (22.22 mm long by 14.97 mm wide) and some tiny ear bones illustrated in figures 4-6, survived more or less intact. The measurements of the incus bone are 6.35 mm wide by 6.01 mm long.



Fig. 1. Some of the larger occipital and parietal fragments with endocranial lesions.

¹ See the preliminary report in this volume p. 286 with indication of the find spot, fig. 20, and a photograph, fig. 21.

² An earlier intramural pithos burial of a child in an EMII context is attested at Nopigeia in West Crete, see discussion and ref. in n. 27, below.

³ Many thanks to Anaya Sarpaki, who sieved the residues for organic remains.



Fig. 2. Magnification of occipital endocranial lesions.



Fig. 3. Magnification of parietal endocranial lesions.

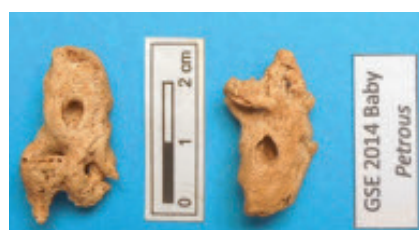

Fig. 4. Right and left petrous bones.



Fig. 5. Greater wing of the left sphenoid.



Fig. 6. Ear bones – incus, malleus.

Dentition

Twelve tooth germs (see Fig. 7) recovered from the residue were identified as the following:

$$\begin{array}{c} d\ c\ b\ | \ a\ b\ c\ d \\ \hline c\ a\ | \ a\ c\ d \end{array}$$

Mesiodistal crown diameters and crown heights are recorded in Table 1.

Since tooth germs begin to develop prenatally, they are good criteria for gestational age determination. Incisors, which begin initial calcification at 4 to 4.5 months in utero, have 60-80% of their crowns formed at birth, whereas canines approximately 30%, while first molars have a complete occlusal cap, maxillary molars being more completely calcified than other molars.⁴ This infant's incisor and canine development corresponds to a full-term embryo, however, the occlusal caps of the molars are not complete, while the enamel of the incisors appears malformed (see Fig. 7).

Measurements in mm	Mesiodistal Crown D	Crown Ht
<i>Upper R lateral incisor</i>	4.08	3.87
<i>Upper L central incisor</i>	6.24	3.92
<i>Upper L lateral incisor</i>	4.69	3.52
<i>Lower R central incisor</i>	3.75	4.32
<i>Lower L central incisor</i>	3.90	4.39
<i>Upper canine</i>	4.62	3.28
<i>Upper canine</i>	[4.09]	3.13
<i>Lower R canine</i>	3.42	2.80
<i>Lower L canine</i>	3.02	2.22
<i>Upper L molar</i>	6.36	3.62
<i>Upper R molar</i>	6.37	3.51
<i>Lower L molar</i>	6.54	3.69

Table 1. Tooth measurements.

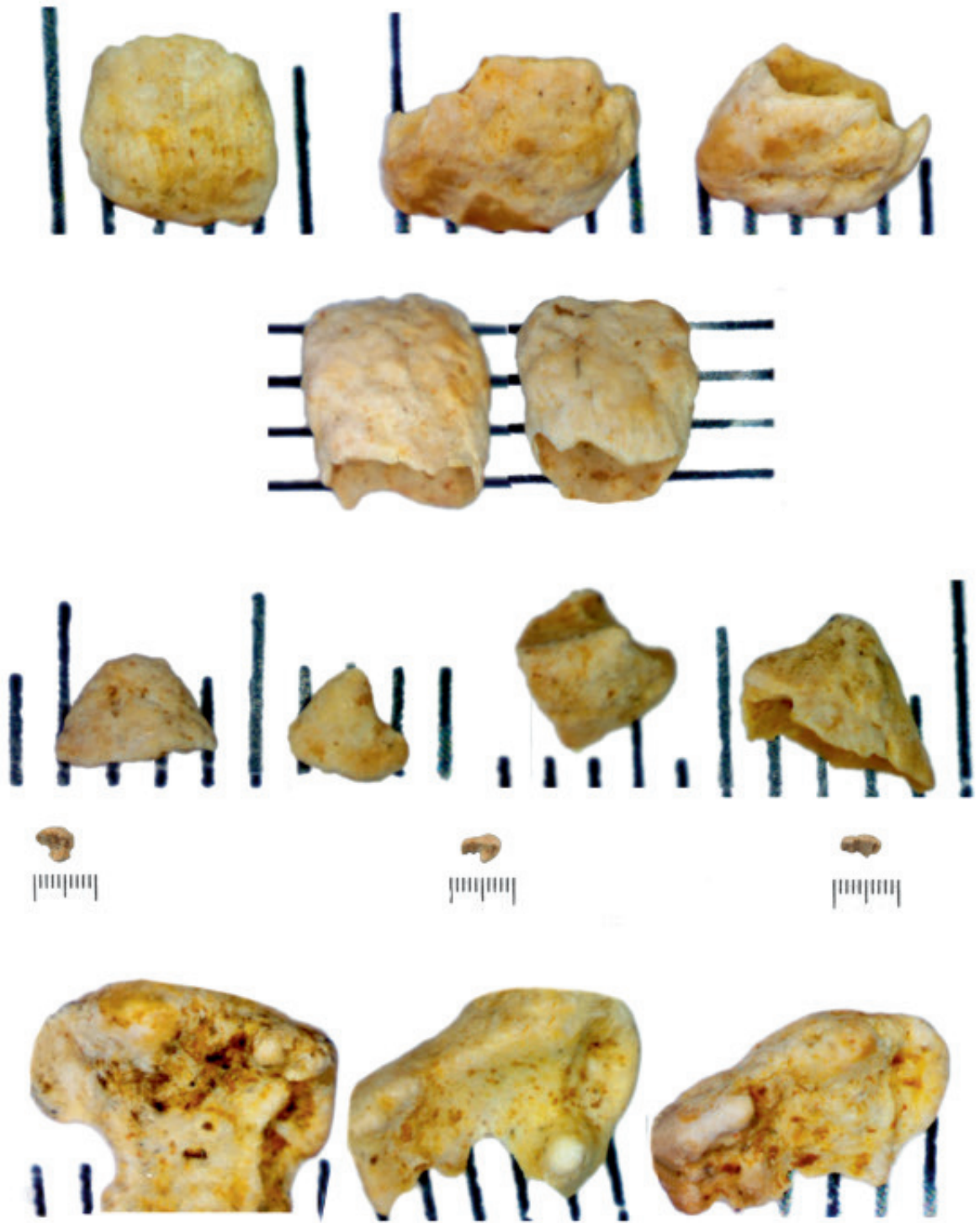


Fig. 7. Partially formed crowns of deciduous teeth on a millimetre grid.

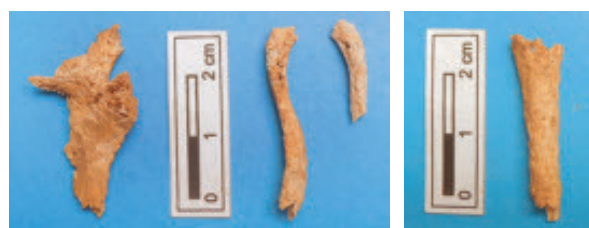

Fig. 8. Right scapula, the clavicles and the right distal humerus shaft.




Fig. 10. Right ulna. Fig. 11. Manual phalanges.

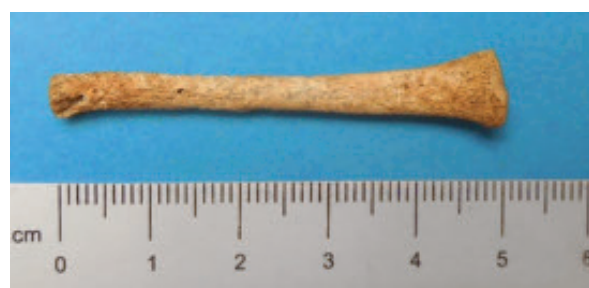

Fig. 9. Right radius.



Fig. 12. Ribs.

Post-Cranium

The baby's upper torso and limbs are represented by the clavicles, the right scapula and the right distal humerus (Fig. 8), the right radius (Fig. 9) and ulna (Fig. 10), some manual phalanges (Fig. 11) and a collection of ribs (Fig. 12). The only complete long bone was that of a right radius measuring 49.82 mm, its length corresponding to that of a 39-week embryo.

Table 2 records the measurements of the complete manual phalanges.

Proximal manual phalanges	mm	Distal manual phalanges	mm
Ray 1 (thumb)	6.91	Ray 1 (thumb)	5.82
Ray 2 (index)	9.85	Ray 5 (?)	2.57
Ray 3	10.5		

Table 2. Measurements of complete manual phalanges.

The lower limbs are represented by the femurs, tibias and fibulas, metatarsals and pedal phalanges, which are illustrated in Figs 13-15. Measurements of the incomplete long bones and of the metatarsals and pedal phalanges are recorded in Tables 3-4.

Conclusion

Despite the fragility of the pit burial and the noticeable absence of the pelvic bones and vertebrae (Fig. 16), enough of the skeleton is present to conclude that it was probably a low birth weight, full-term baby. Enamel hypoplasia is a correlate of low birth weight infants.⁵ Lesions like those on the internal surfaces of the occipital and parietal bones, illustrated in Figs 1-3, may have a variety of causes in young children,⁶ but in newborn babies the most likely causes are either bacterial infection transmitted through the placental blood supply or foetal distress due to poor maternal nutrition. In preterm infants intra-cranial haemorrhage may occur as a result of vitamin

⁵ Seow, Humphrys & Tudehope 1987, 221-5.

⁶ Lewis 2004, 82-97.

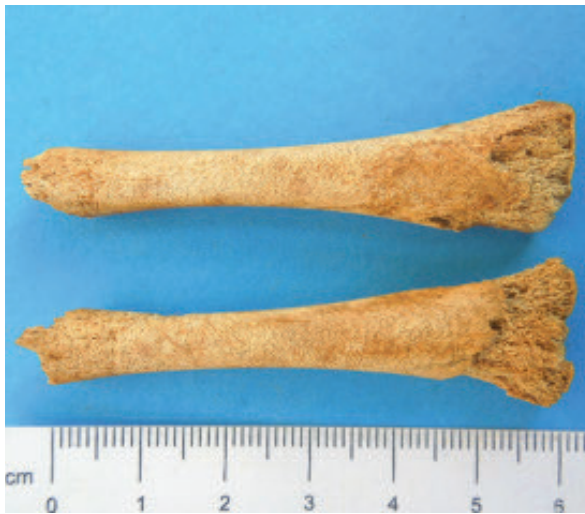

Fig. 13. Femurs.

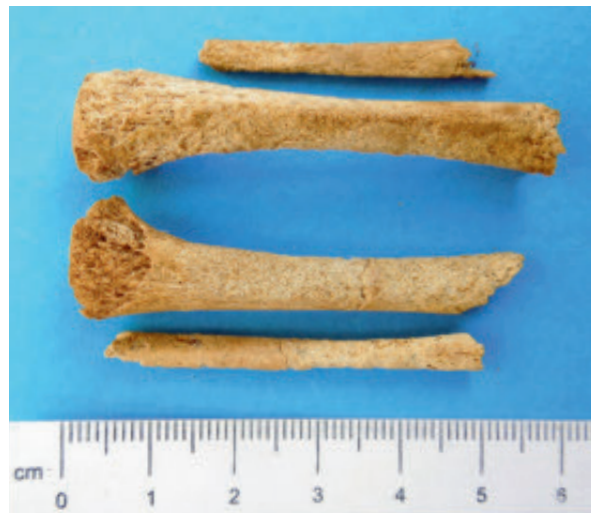

Fig. 14. Tibias and fibulas.

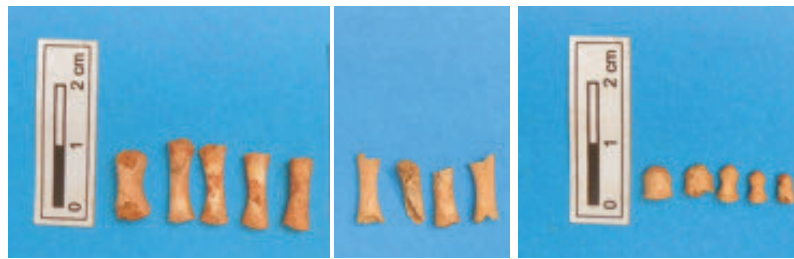


Fig. 15. Metatarsals and pedal phalanges.

Bone	mm
R Scapula	31.98
R Glenoid Ht.	8.35
R Clavicle	31.18
L Clavicle	16.94
R Humerus	30.98
R Ulna	32.85
R Femur	62.48
L Femur	61.59
R Tibia	52.23
L Tibia	55.01
R Fibula	45.01
L Fibula	35.82

Table 3. Measurements of incomplete bones.

Metatarsals	mm
1st	11.42
2nd	13.06
3rd	13.55
4th	12.37
5th	11.87
Proximal pedal phalanges	
mm	
Ray 1 (big toe)	5.38
Ray 2	5.77
Ray 3	4.72
Ray 4	4.50
Distal pedal phalange	2.37

Table 4. Measurements of complete bones.

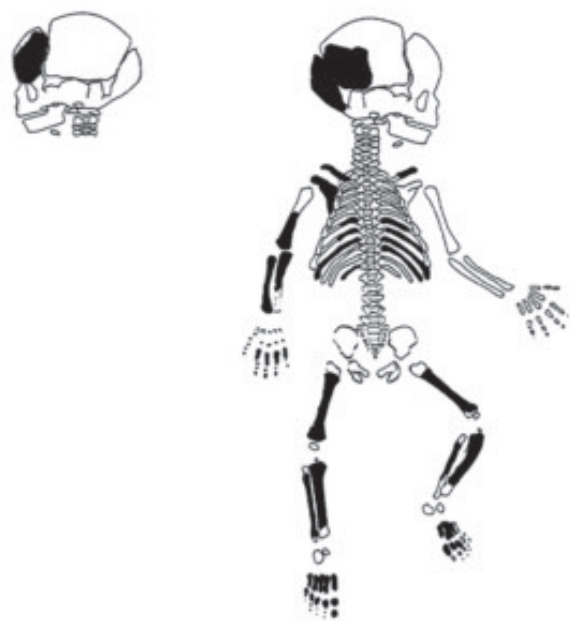


Fig. 16. Infant skeleton, dark areas preserved.

or mineral deficiency. Perinatal death might have been due to poor maternal nutrition, poor hygiene or neonatal infection. Nevertheless, it should be noted that even today in the developed world, with advanced technology, it is more often than not impossible to diagnose the precise cause of a perinatal death.

Discussion:

The Pit L baby burial is the second infant burial to be found in the Ag. Aikaterini Square excavation. A similar burial in a shallow pit was found previously under the LM IIIB:2 floor of a house,⁷ less than a metre from the hearth in the centre of room E, which measured 6.5 x 4.5 m². Two iliac bones in an excellent state of preservation were the only surviving remains of the burial of a premature infant of c. 37 weeks gestation. There were no gifts. Items recorded on the beaten clay floor were two bowls, found in dif-

ferent corners, a small tripod cooking pot and a cooking dish, which suggested that the room was a domestic area used for the preparation of food.

Interments inside a house, or in an open area such as a courtyard, but within a settlement, are designated intramural, in contrast to burials in extramural cemeteries. Intramural burial of infants either inside or outside a home, often in areas where domestic activities took place, are characteristic of the earliest settled communities of the Near East. Such burials have also been found at Neolithic Knossos;⁸ the Minoans, however, normally buried their dead extramurally.

On the Greek mainland, intramural burial of infants was practised throughout the Bronze Age with interments in earth-dug graves, stone-lined cists or pots, or under large sherds (see locations in Fig. 17). At some sites, such as Asine, with 57 infant or child burials (forty-five in pits, six in pithoi, five in cists and one in a brick enclosure), they occur in significantly large numbers.⁹ By contrast, in the Minoan Bronze Age intramural burials of infants or children are relatively scarce, although now known at several sites throughout the island.

The highest concentration of infant burials of various types has been found at the Knossos Stratigraphical Museum Extension site, where the majority of graves are pit burials, while a few pit burials have been found at Gypsadhes¹⁰ and the Unexplored Mansion (see Table 5).¹¹ Elsewhere, intramural infant burials appear sporadically, in small numbers. So far there is only one cist burial from the Unexplored Mansion at Knossos, but there are eight pot burials from six different localities, dating to the EM II (Nopigeia), LM IA (Petras and Sissi) and to LM IIIA₂/IIIB periods at Palaikastro, Knossos and Phaistos (Fig. 17)¹².

Most of the burials found at the Knossos Stratigraphical Museum Extension site were dated to the post-Palatial LM

7 O. & E. Persson 2003, 276; McGeorge 2003, 301-3.

8 Evans 1964, 132-240; McGeorge 2013, 1-20.

9 Frodin & Persson 1938.

10 Hogarth 1899-1900, 70-84.

11 Popham 1984.

12 MacGillivray, Driessen, Macdonald & Smyth 1988, 259-82; McGeorge forthcoming.

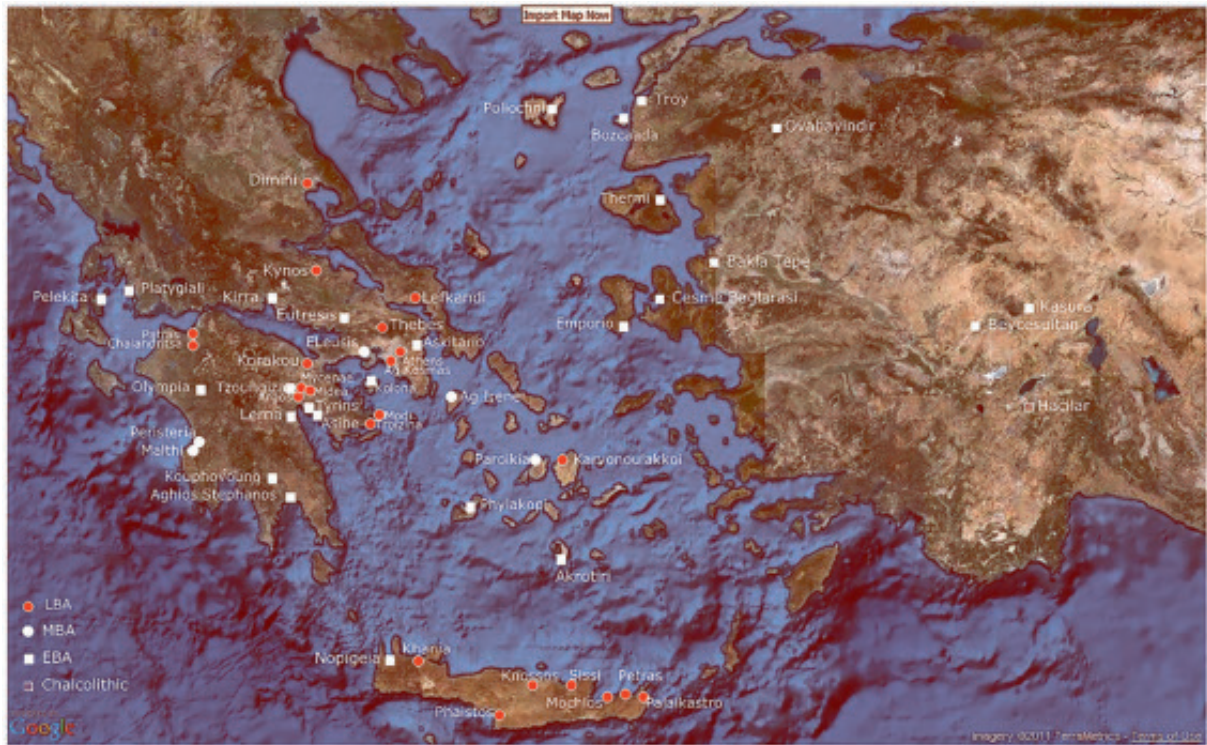


Fig. 17. Bronze Age sites with intramural infant burial.

IIIC/Subminoan period and their appearance was attributed to the ingress and cultural influence of Mycenaeans.¹³ The Minoans had prospered from trade that flowed between Crete and the mainland, but a shift in the relationship with the Mycenaeans becoming politically dominant is undeniable once Linear B began to be used for official administrative documents.¹⁴ The new proto-Greek-speaking overlords adopted a syllabary and an administrative system very like the one they had overrun. Late Minoan Crete became a Mycenaean dominion, submitting to a change of language and aesthetic tastes, and new divinities. However, the date of the Linear B tablets is contested. Most people accept an LM IIIA:1/A:2 date for the fire in

which the tablets were baked,¹⁵ but a recent reappraisal of the data suggests LM IIIB:1 as the time of the destruction.¹⁶

In Crete, apart from the Early Minoan pithos burial at Nopigeia, the evidence suggests that intramural burials occurred progressively from the LM I period. In East Crete (Fig. 17) there are intramural, infant, pot burials that pre-date the warrior burials and the Linear B tablets: the one at Petras in an inverted pithos is dated to LM IA;¹⁷ two at Sissi in pyxis-type vases are also dated to LM IA.¹⁸ At Mochlos what must be assumed to have been a subfloor pit burial, since it was recovered after floatation of the deposit, was dated to LM IB.¹⁹ Moreover, the pit

13 Warren 1980-1, 73-92; Warren 1982-3, 63-87; though some could be early, cf. McGeorge & Warren, forthcoming.

14 The ascendancy of a Mycenaean warrior caste is seen earlier at Knossos, signalled by the appearance of burials with weapons in LMII. Hood 1952; 1956.

15 Popham 1970.

16 For the thoroughly documented alternative argument, see Hallager & Hallager, 2015, 99-124.

17 McGeorge 2012, 291-304.

18 Dreissen 2011.

19 Soles & Walker 2003, 135-47, pls 32-6.

Site	Burials	Date	Types
Nopigeia Kissamos	1	EM II	Pithos
Gypsadhes	1	LM IA or IB	Pit
Unexplored Mansion	4	LM IA	1 cist/3 pits
Stratigraphical Museum	23	MM IIIB (?) /LM IA LM II-SM Hellenistic/Roman	Pits (16 +) 1 built grave 1 under lekane 1 under quern 1 on stone/block
Petras	1	LM IA	Pithos (inverted)
Sissi	2	LM IA	Pyxis-type vases
Mochlos	1	LM IB	Pit
Palaikastro	1	LM IIIA ₂ /IIIB	Decorated amphoroid krater
Phaistos	2	LM IIIB	Double-handled globular cooking jar / tubular vase
Khania	1	MM III/LM I	Pit
	1	LM IIIB ₂	Pit

Table 5. *Bronze Age sites in Crete with intramural burials.*

burials at Gypsadhes and the Unexplored Mansion have been dated to LM IA or IB. There are several possible explanations, one being that it is a mainland-derived idea introduced by Mycenaean elements in the population entering Crete earlier than is generally believed.

However, intramural burial of infants is not a uniquely Mycenaean burial rite. Syro-Palestinian peoples had practised the intramural burial of infants in jars ever since the invention of pottery²⁰ and had long established contacts with the Minoans²¹ According to Levantine mythology

the entrance to the netherworld was Mt. Knkny, the name of which is a derivative of the Ugaritic, Akkadian, Aramaic and Canaanite words for 'storage jar' (*knkn*), referencing the use of storage jars for burial.²² Knkny is mentioned specifically in the Ugaritic Tale of Aqhat,²³ recorded in the early 14th century BC.²⁴ Since trade was the portal for the intangible ebb and flow of ideas, religious beliefs and customs that paralleled the flow of goods and people, the rite may have been practised by immigrants, or the practice may have come about through cross-cultural consumption of an attractive ideology.²⁵

²⁰ McGeorge 2013.

²¹ They believed Kothar, their god of technology, resided in Crete; Cline 1995, 276.

²² Astour 1980; Pritchard 1969, 139, quoted by Ilan 1995, 136.

²³ McGeorge 2013, 1-20.

²⁴ The text, written down in alphabetic cuneiform by the scribe Ilimilku, was found at Ras Shamra in the house of the High Priest, which was destroyed by an earthquake in 1365 BC. See Schniedewind & Hunt 2007, 8-29.

²⁵ Burying infants in domestic contexts may be related to primitive perceptions of the mechanisms of human reproduction, fertility and customs, which were believed to promote the generation/regeneration of new life. See McGeorge 2012.

At present, only one Early Minoan intramural jar burial dated to EM II is known in West Crete at Nopigeia, Kissamos, almost 60 miles or 100 km across the sea from Cape Malea in the Peloponnese. A three-year-old child was interred with two obsidian blades, in a pithos (c. 0.50 cm tall) at the corner of a building in an open area paved with pebbles.²⁶ The pithos lay on its side in a shallow pit, the mouth of the jar pointing westwards. In this period, Nopigeia appears to have had contacts with the Peloponnese,²⁷ where intramural burial was practised. Although several Bronze Age settlement sites have been excavated in West Crete since the 1960s,²⁸ only Nopigeia in the early Bronze Age and Kastelli Khania in the late Bronze Age have produced intramural infant burials.

Intramural burials of similar early date to that at Nopigeia have been found at many island sites across the Aegean, in the North Aegean, Dodecanese and Cyclades. Specifically, Early Bronze Age intramural infant burials are known from the islands of Astypalaia,²⁹ Samos, Lesbos, Chios, Limnos, Melos, Thera, Paros and Aegina.³⁰ These burials may be linked to a wave of immigration from Asia Minor where Early Bronze Age sites with intramural burials are numerous (Fig. 17),³¹ and/ or from further East, where such burial customs had been practised from time immemorial.³² Moreover, according to historical tradition recorded by Herodotos and Thucydides, the Aegean islands were colonized by immigrant Carians and Phoenicians³³ who, along with troublesome pirates, were later expelled by Minos.³⁴

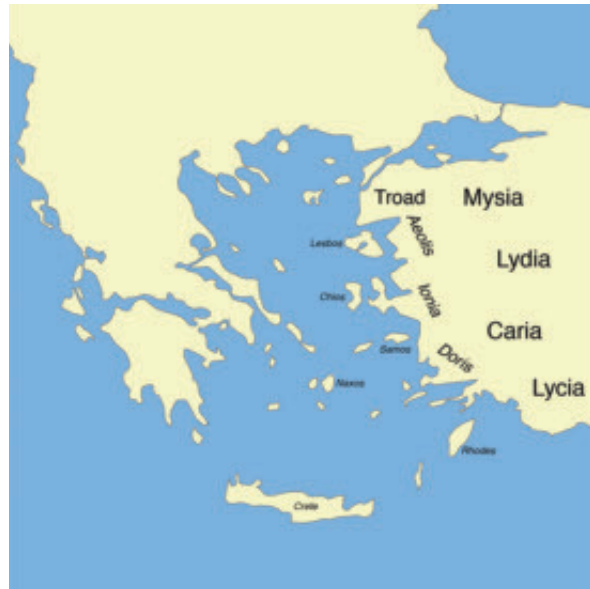

Fig. 18. *Asia Minor.*

Recent events in the Mediterranean have made us all aware that human migrations are motivated by many layered dynamics. Interestingly, all the LM intramural burials on Crete have been found at centres with vibrant overseas contacts that might have attracted foreigners seeking new opportunities, or foreigners who came involuntarily. Linear B tablets mention women, possibly sold into slavery, engaged in weaving, giving their cities of origin, which some Mycenologists identify with place names in Western Anatolia.³⁵ The case against using symbolism from diverse cultural origins to distinguish between Minoans,

²⁶ Karantzali 1997, 66-81.

²⁷ A study of EM ceramics from the Nopigeia area posited that the recipes/technological expertise used to manufacture the pottery originated in the Peloponnese. See Nodarou 2011.

²⁸ Debla, Kastelli Khania, Nerokourou, Nopigeia, Samonas and Stylos.

²⁹ Investigation of a 3rd-millennium BC settlement on the headland of Vathy, Astypalaia unearthed Early Bronze Age pot burials of newborn infants in 2012 and 2013. One of the containers was a wide-mouthed jar sealed with a stone lid. Micro-excavation of the contents revealed near the base of the vase an imprint of the cloth in which the infant had been wrapped. A second infant was found in a two-handled EC I bowl. See BCH 2013 Chronique des Fouilles en Ligne no. 4703. Information and references were kindly provided by Prof. A Vlachopoulos.

³⁰ McGeorge 2013, 2.

³¹ At Bakla Tepe, Çeşme-Bağlararası, Troy, Alişar, Boğazköy, Kalınkaya, Kusura, Beycesultan, Hacılar II, Ovabayındır and more. See Stech-Wheeler 1974, 415-25; Massa & Şahoğlu, 2011.

³² McGeorge 2013.

³³ Carians from southwest Anatolia, and Phoenicians from Syro-Palestine.

³⁴ Herodotos 1.171; Thucydides I. 8.

³⁵ Ventris & Chadwick 1973, 156, 410 identify: Miletus/Mi-ra-ti-ja; Lemnos/Ra-Mi-ni-ja; Knidus/Ki-ni-di-ja; Zephyria/Ze-pu-ra and Asia/A-swi-ja, see Unal 1991.

Mycenaeans or other ethnicities in the Late Minoan burial record has been argued vigorously, offering high status competition as an alternative explanation.³⁶ However, an infant subfloor pit burial without offerings does not infer high status; nor does it appear to be a typically Minoan burial practice.

In conclusion, the recently excavated pit burial, dated to MMIII/LMI,³⁷ could be evidence of the spilling into West Crete, earlier than is generally believed, of mainlanders/Mycenaeans, or perhaps other foreigners practising this burial rite, drawn to Minoan Crete at the height of her prestige and prosperity.³⁸ Such an early occurrence of intramu-

ral infant burial suggests that a subtle migration process may have been active in MMIII, initiating gradual transformation of the population's social and genetic matrix, earlier than was previously supposed and prior to the usurpation of political power by a proto-Greek speaking Mycenaean élite who were backed, as we now know, by military might.³⁹

P. J. P. MCGEORGE
British School at Athens
35 Evoikou, 19009 Rafina
Greece
tinamcgeorge@gmail.com

³⁶ Preston 2004, 321-48.

³⁷ In absolute dates: 1700-1450 BC, according to Whitelaw 2000, 223-6.

³⁸ The people who buried their dead in the LM IIIA:2 pit caves excavated at Palama Street may have been immigrants from the East; see Hallager & McGeorge 1992, 28.

³⁹ Documented by the very impressive Achaean warrior tombs, including shaft graves, excavated southeast of the Kastelli settlement, near the modern law courts in Khania. See Andredaki-Vlazaki, Rethemiotakis & Dimopoulou-Rethemiotaki, 2008, 102.

Bibliography

Andreadaki-Vlazaki M., G. Rethemiotakis & N. Dimopoulou-Rethemiotaki (eds) 2008
From the Land of the Labyrinth Minoan Crete from 3000-1100 BC Essays, Athens.

Astour, M. C. 1980
‘The netherworld and its denizens at Ugarit’, in *Death in Mesopotamia* (Papers read at the XXVIe Rencontre Assyriologique Internationale, Mesopotamia 8), B. Alster (ed.), Copenhagen, 227-38.

Cline, E. H. 1995
‘Tinker, Tailor, Soldier, Sailor: Minoans and Mycenaeans abroad’, in *Politeia. Society and State in the Aegean Bronze Age* (Aegaeum 12), R. Laffineur & W.-D. Niemeier (eds), Liège, 265-83.

Dreissen, J. 2011
Excavations at Sissi. Vol. II. Preliminary Report on the 2009-2010 Campaigns, Louvain.

Evans, J. D. 1964
‘Excavations in the Neolithic settlement of Knossos 1957-60. Part I’, *BSA* 59, 132-240.

Frodin, O. & A. W. Persson 1938
Asine. Results of the Swedish Excavations 1922-1930, Stockholm.

Hallager, B. P. & P. J. P. McGeorge 1992
Late Minoan III Burials At Khania (SIMA 93), Gothenburg.

Hallager, E. & B. P. Hallager 2015
‘When the saints go marching in’, in *Ein Minoer im Exil, Festschrift für Wolf-Dietrich Niemeier*, D. Panayiot-

poulos, I. Kaiser & O. Kouka (eds), Bonn, 99-124.

Hood, S. 1952
‘Late Minoan Warrior-graves from Ayios Ioannis and the New Hospital Site near Knossos’, *BSA* 47, 243-77.

Hood, S. 1956
‘Another warrior grave at Ayios Ioannis, near Knossos’, *BSA* 51, 81-9.

Hogarth, D. G. 1899-1900
‘Knossos: II. Early Town and Cemeteries’, *BSA* 6, 70-84.

Ilan, D. 1995
‘Mortuary Practices at Tel Dan in the Middle Bronze Age: A reflection of Canaanite Society and Ideology’, in *The Archaeology of Death in the Near East* (Oxbow Monograph 51), S. Campbell & A. Green (eds), Oxford, 117-39.

Karantzali, E. 1997
‘Στοιχεία Πρωτομινωικής Κατοίκησης στα Νοπήγεια Κισάμου’, *ΑΔ* 47-8 (1992-1993), *Α’ Μελέτες*, 66-81.

Lewis, M. E. 2004
‘Endocranial lesions in non-adult skeletons: understanding their aetiology’, *International Journal of Osteoarchaeology* 14, 82-97.

MacGillivray, J. A., J. Driessen, C. Macdonald & D. Smyth 1988
‘Excavations at Palaikastro, 1987’, *BSA* 83, 259-82.

Massa, M. & V. Şahoğlu 2011
‘Western Anatolian Burial Customs during the Early Bronze Age’, in *Across, The Cyclades and western Anatolia during the 3rd millenium BC*, V. Şahoğlu & P. Sotirakopoulou (eds), Istanbul.

McGeorge, P. J. P. 2003
‘Intramural Infant Burials in the Aegean’, in E. Hallager & B. P. Hallager (eds), *The Greek Swedish Excavations at the Agia Aikaterini Square Kastelli, Khania 1970-1986 and 2001* 3, 1 *The Late Minoan IIIB:2 Settlement* (ActaAth-4°) (Appendix 2), Stockholm, 301-3.

McGeorge, P. J. P. 2012
‘The intramural infant jar burial at Petras: context, symbolism, eschatology’, in *Petras Siteia: 25 Years of Excavations and Studies* (MoDIA 16), M. Tsipopoulou (ed.), Athens, 291-304.

McGeorge, P. J. P. 2013
‘Intramural Infant Burials in the Aegean Bronze Age, Reflections on symbolism and eschatology with particular reference to Crete’, in *Le Mort Dans La Ville, Pratiques, contextes et impacts des inhumations intra-muros en Anatolie, du début de l’Âge du Bronze à l’époque romaine*, Olivier Henry (ed.), Istanbul, 1-20.

McGeorge, P. J. P. forthcoming
‘Due Sepoltura A Enchytrismos Del TMIIIB In Una Casa A Festos’, in *Il complesso della Casa a ovest del Piazzale I de Festòs (scavi 1965-1966)* (Quaderni di Archeologia Cretese, Università di Catania – Monografie), A. Padova (ed.).

McGeorge, P. J. P. & P. Warren forthcoming
Intramural Burials from the Knossos Stratigraphical Museum Excavations 1978-1981.

Nodarou, E. 2011

Pottery production distribution and consumption in Early Minoan West Crete: an analytical perspective (BAR International Series 2210), Oxford.

Persson, O. & E. 2003

'A Note on the Foetus', in *The Greek Swedish Excavations at the Agia Aikaterini Square Kastelli, Khania 1970-1986 and 2001* 3, 1 *The Late Minoan IIIB:2 Settlement* (ActaAth-4°), E. Hallager & B. P. Hallager (eds), Stockholm, 276.

Popham, M. R. 1970

The Destruction of the Palace at Knossos. Pottery of the Late Minoan IIIA Period (SIMA 12), Gothenburg.

Popham, M. R. 1984

The Minoan Unexplored Mansion at Knossos (BSA Supplement 17), London.

Preston, L. 2004

'A Mortuary Perspective on Political Changes in Late Minoan II-III B Crete', *AJA* 108, 321-48.

Pritchard, J. B. 1969

Ancient Near Eastern Texts Relating to the Old Testament, Princeton.

Scheuer, L. & S. Black 2000

Developmental Juvenile Osteology, Oxford.

Schniedewind, W. M. & J. H. Hunt 2007

A Primer on Ugaritic Language, Culture, and Literature, Cambridge, 8-29.

Seow, K. W., C. Humphrys & D. I.

Tudehope 1987

'Dental enamel defects in low birth weight children', *Paediatric Dentistry* 9:3, 221-5.

Soles, J. & C. Walker 2003

'Human Skeletal Remains', in *Mochlos IA: Period III. Neopalatial Settlement on the Coast: The Artisans' Quarter and the Farmhouse at Chalinomouri. The Sites* (Prehistory Monographs 7), J. Soles & T. M. Brogan (eds), Philadelphia, 135-47.

Stech-Wheeler, T. 1974

'Early Bronze Age Burial Customs in Western Anatolia', *AJA* 78, 415-25.

Unal, A. 1991

'Two peoples on both sides of the Aegean: Did the Achaeans and Hittites know each other?', in *Essays on Anatolian and Syrian Studies in the 1st and 2nd millennium BC*, H. I. H. Prince Takahito Mikasa (ed.), Wiesbaden, 16-44.

Ventris, M. & J. Chadwick 1973

Documents in Mycenaean Greek (2nd ed.), Cambridge.

Vlachopoulos, A. G. 2013

BCH 2013. Chronique des Fouilles en Ligne no. 4703 accessed December 13, 2015. <http://chronique.efa.gr/index.php/fiches/voir/4703/>

Warren, P. M. 1980-1

'Knossos Stratigraphical Museum Excavations, 1978-80. Part I', *Archaeological Reports* 27, 73-92.

Warren, P.M. 1982-3

'Knossos Stratigraphical Museum Excavations 1978-82. Part II', *Archaeological Reports* 29, 63-87.

Whitelaw, T. 2000

'Beyond the Palace: A Century of investigation in Europe's oldest city', *Bulletin of the Institute of Classical Studies* 44, 223-6.